MANAGING OCULAR TRAUMA WITH SCLERAL LENSES

These devices can improve many patients' visual performance and comfort and thus enhance their quality of life.

BY RYAN MCKINNIS, OD, FAAO, FSLS

Traumatic ocular injuries can significantly reduce a patient's ability to function. Symptoms vary, depending on the injury, and can range from mildly irritating to visually debilitating.

Modern scleral lenses can simultaneously treat substandard vision and improve ocular comfort in patients with traumatic injuries. These devices require a great deal of expertise to properly fit and manage patients, but, with the right amount of application and skill, clinicians may be able to significantly improve a trauma patient's visual performance.

OCULAR CORRECTION

The type of ocular correction required after trauma largely depends on the degree of deformity present.

Penetrating Injuries

Penetrating injuries often require highly advanced optical devices such as the EyePrintPro (EyePrint Prosthetics). These devices are typically created from a mold of the ocular surface. Technological advances such as the Cornea Scleral Profile scan on the Pentacam (Oculus Optikgeräte) permit the creation of similar devices without requiring a mold.

Minimal Physical Injury

If a patient's ocular shape was affected only minimally by a traumatic incident, then it is entirely appropriate to fit that patient with a more traditional scleral lens. Care must be taken to protect the compromised corneal structure from further insult such as hypoxia. Fitting patients according to Michaud's criteria can help to prevent hypoxic complications. Specifically, patients should be fit with no more than 200 µm of central lens clearance, lens thickness should not exceed 250 µm, and the lens material should have the highest possible oxygen transmissibility.[1]

Concurrent Ocular Surface Disease

Patients who have experienced ocular trauma may also present with concurrent ocular surface disease. This may be due to the tear film's inability to cover the irregular surface properly, or because trauma has caused tear production to decrease. Lens materials with a low wetting angle may promote lens surface wettability, but the most common technique to increase wettability is to coat the lens surface with Tangible Hydra-PEG (Tangible Science). This coating encapsulates the scleral lens surface and resists deposits while promoting lens surface wetting. Because exposure to harsh chemicals, cleaners, or tap water can strip the coating from the lens surface, it is important to educate patients on the proper care and handling of lenses treated with Tangible Hydra-PEG.

WHEN THE JOB CALLS FOR SCLERAL LENSES

Scleral lenses can largely be classified into two broad categories according to the nomenclature adopted by the Scleral Lens Education Society. Lenses that are up to 6 mm larger than the horizontal visible iris diameter are classified as *mini scleral lenses* and may often be fit with less corneal clearance than larger designs. Mini scleral lenses

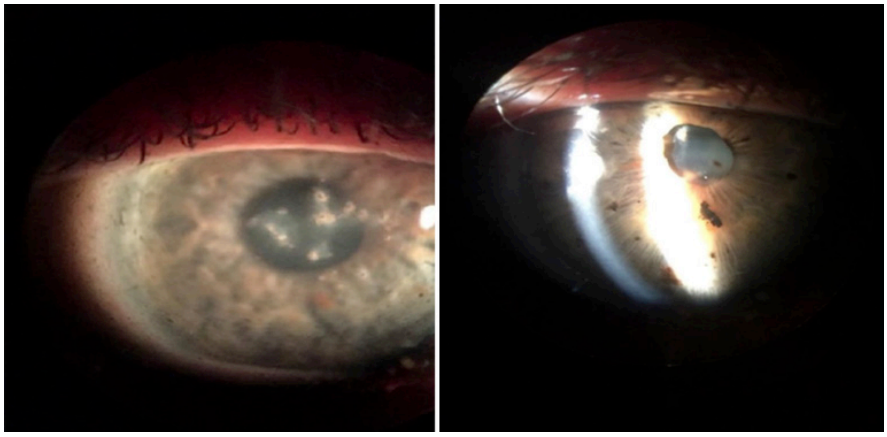

Figure 1. Note the diffuse foreign bodies embedded throughout the ocular structures after a firework exploded near the patient's face.

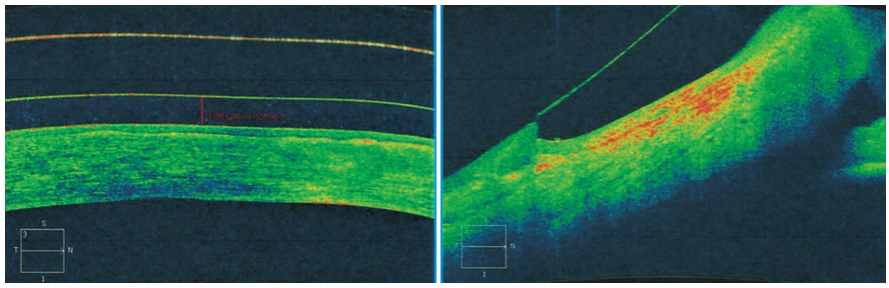

Figure 2. OCT imaging showing proper central corneal clearance and peripheral landing of the scleral lens.

promote oxygen availability to the corneal structures and may also require less back surface toricity to match the inherent toricity of the globe.

Lenses that possess a diameter greater than 6 mm more than the horizontal visible iris diameter are known as *large scleral lenses*, possess greater sagittal depth, and thus have the ability to fully vault extreme differences in ocular anatomy. Greater amounts of back surface toricity are typically required to fit the nonrotational symmetric globe as one extends further from the limbus. The practitioner must also carefully monitor for any signs of hypoxia, as these larger diameter lenses may have significant clearance differences and thus likewise limit oxygen availability in the areas exhibiting a high degree of clearance.

CASE EXAMPLE

A 47-year-old man was referred from a dry eye clinic for a possible scleral lens fitting. The patient had experienced moderate to severe ocular discomfort (nearly constant burning and stinging) and significant glare and halos since a firecracker exploded near his face. Diffuse foreign bodies were embedded throughout the ocular structures of each eye (Figure 1). Since the injury, the patient had been relying on spectacle correction because wearing soft contact lenses had become uncomfortable.

Epithelial foreign bodies were removed. Those that were prevalent in other structures were deemed inactive, and removal was not attempted. The patient was fit with a SynergEyes VS scleral lens (SynergEyes) in an effort to improve ocular comfort and quality of life and to reduce aberrations. The scleral lenses incorporated front toric optics to provide the best possible vision and back surface toricity to optimize the fit. Central clearance was 188 µm on OCT (Figure 2), meaning that the oxygen supply was adequate to promote healthy corneal physiology. To aid with surface wetting, each lens was treated with Tangible Hydra-PEG.

The patient reported a significant improvement in quality of life after he began wearing the scleral lenses. Ocular aberrations decreased significantly, and he reported no longer experiencing chronic irritation of the ocular surface. The patient should be able to continue with normal activities as long as he is able to wear scleral lenses. It is anticipated that the patient will be reliant on scleral lenses long-term in order to function properly.

KNOW WHEN TO FOLD 'EM

Concurrent treatment of a patient's ocular surface disease is paramount to achieving success. If the practitioner does not possess the tools and training necessary to manage ocular surface disease, then it is recommended that a proper referral occur. Measuring tear film osmolarity and the presence of inflammatory mediators, and viewing the structure and function of the meibomian glands, are necessary to properly treat advanced ocular surface disease.

Most patients who experience visual decline following ocular trauma notice a significant improvement with scleral lenses. However, patients may struggle with insertion and removal. When feasible, a soft contact lens may still be of use. There may unfortunately be cases in which the ocular trauma is too severe and no form of optical correction can restore functional vision.

SUCCESS WELL-EARNED

Treating patients with ocular trauma can be immensely challenging and rewarding. In order to provide the best opportunity for success, the practitioner must have a deep toolbox of optical correction options. Each patient is unique and presents with his or her own inherent challenges, but when success is achieved, there is no better feeling. ■

1. Michaud L, van der Worp E, Brazeau D, Warde R, Giasson CJ. Predicting estimates of oxygen transmissibility for scleral lenses. *Cont Lens Anterior Eye*. 2012;35(6):266-271.

RYAN MCKINNIS, OD, FAAO, FSLS

- Optometrist at the Cleveland Eye Clinic, with locations in the greater northeast Ohio area
- drmckinnis@clevelandeyeclinic.com
- Financial disclosure: Key Opinion Leader (SynergEyes)